

Congenitally Missing Upper Laterals. Clinical Considerations: Orthodontic Space Closure

¹Muhamad Abu-Hussein, ²Nezar Wattad

¹University of Naples Federico II, Naples, Italy, Department of Pediatric Dentistry, University of Athens, Greece.

²Triangle R&D Center, Kafr Qara, Israel, Clinics and Policlinics for Dental, Oral and Maxillofacial Diseases of the Bavarian Julius-Maximilian-University, Wuerzburg, Germany.

ABSTRACT:

Agenesis of the maxillary lateral incisors is a common finding with esthetic and functional problems. The treatment options available are space closure by canine substitution and space opening for future prostheses. The aim of this article is to make a report and critical evaluation of the current perspectives treatment options available in the contemporary literature. Clinical cases of each treatment approach are also presented.

Keywords: Agenesis, lateral incisors, maxilla, space opening, reconstruction

Corresponding Author: Dr. Abu-Hussein Muhamad, DDS, MScD, MSc, DPD, FICD
123 Argus Street, 10441 Athens, Greece. Email: abuhusseinmuhamad@gmail.com

INTRODUCTION:

The maxillary lateral incisor is one of the teeth with the highest prevalence of congenital absence. Because of the location of this problem, the patients with maxillary incisors agenesis usually seek orthodontic treatment for esthetic reasons and present high expectations. The orthodontist treatment planning these cases usually faces a key question: to open or to close the missing laterals spaces?¹

Agenesis of one or more teeth, also known as hypodontia, is the most common developmental dental anomaly in man. Several terms are used in the literature to describe missing teeth; Anodontia is the complete absence of teeth; Oligodontia is referred to as partial anodontia, characterized by having six or more teeth absent, not including the third molars; Hypodontia is a term used to denote that teeth are missing, but usually less than six. Hypodontia not only describes missing teeth, but it also may denote that the size or shape of teeth is reduced as well.^{1,2,3}

Tooth agenesis affects the permanent dentition more frequently than the primary dentition. The incidence for permanent tooth agenesis ranges from 2.30% - 6.01%,

excluding third molars.¹⁻³ In the primary dentition, tooth agenesis ranges from 0.20% - 0.90%.^{2,3}

The most common missing tooth is the third molar, with an incidence of about 20%. As for which tooth is the second and third most common, the literature varies. Some studies show that the maxillary lateral incisor is the second most common missing tooth. Others show that the absence of the mandibular second premolar is more frequent than the maxillary lateral incisor.⁴

A significant number of people in the population are congenitally missing permanent maxillary lateral incisors. The demand for orthodontic treatment by these people is high because of the obvious impact that this condition has on both dental and facial esthetics. This is a challenging situation that every orthodontist will encounter on a regular basis.²

There are multiple treatment options when planning these patients. One option is to close the lateral incisor space by moving the canine until it is adjacent to the central incisor and then reshaping it to look like the lateral incisor through a process called canine substitution. The other option is to place the canine in its natural position within

the dental arch, filling the void left by the missing lateral incisor with either a single-tooth implant or a tooth-supported restoration.⁵

A thorough diagnostic protocol should be used in determining which option is best for each patient.⁶ Many articles have been written suggesting that there are certain dental and facial criteria that should be analyzed before deciding which option to choose. They include malocclusion, amount of crowding, profile, canine shape and color, and level of the lip. Other criteria to consider, that isn't mentioned often in the literature is the position in the dental arch where the canine erupts.⁶

A recent study by Rendon found that when the permanent maxillary lateral incisor was missing, the canine erupted in a more medial position within the dental arch closer to the mid-alveolar plane.³ Araujo also suggests that in patients with congenitally missing maxillary lateral incisors, canines frequently show a mesial pattern of eruption, with a final position in the dental arch that is adjacent and parallel to the central incisors, and that such a condition favors canine substitution.⁷

In patients that are congenitally missing maxillary lateral incisors, one more criteria to consider that isn't mentioned in the literature is the gingival margin of the maxillary canine that erupts into the space normally occupied by the maxillary lateral incisor, and its relationship to the gingival margin of the maxillary central incisor. Is the relationship between the gingival margins like a normal maxillary central incisor/maxillary canine relationship, where the gingival margins are at the same level? Or, is the relationship between the gingival margins of the maxillary central incisor and canine more like a maxillary central incisor/maxillary lateral incisor relationship, where the lateral incisor gingival margin is more incisal than the gingival margin of the maxillary central incisor?^{8,9}

Treatment planning for these patients can be challenging. There are many

concerns one needs to be aware of when planning these cases because the congenital absence of one or both of these teeth introduces an imbalance in maxillary and mandibular dental arch lengths in the permanent dentition. The most predictable way to achieve the optimal esthetic and functional result is to use an interdisciplinary team consisting of a general dentist, orthodontist, periodontist, oral surgeon, and prosthodontist. Together, they should elaborate and create the patient's treatment plan and communicate throughout the course of treatment to make sure that all aspects of treatment are considered and the overall treatment objectives are achieved.^{8,9,10}

There are multiple options that exist for treating these patients. The space, sometimes closes spontaneously. If not, the space can be closed orthodontically through a process called canine substitution. This is done by moving the maxillary canine into the position normally occupied by the maxillary lateral incisor and then reshaping it to look more like the lateral incisor. The other option is to place the canine in its normal position within the arch, creating space for either a single-tooth implant or a tooth-supported restoration.^{11,12}

When deciding which treatment option to use, primary consideration should be given to the least invasive option that conserves tooth structure and satisfies the expected esthetic and functional objectives. Whichever option is chosen, it is important to complete a diagnostic wax-up. This helps the interdisciplinary team evaluate the final occlusion and determine if an esthetic final result is obtainable.¹³

There are two principal types of malocclusion that allow for canine substitution to occur. The first one is an Angle Class II malocclusion with no crowding in the mandibular arch indicating that no extractions are necessary. This scenario would leave the molars in Class II. The second one is an Angle Class I malocclusion with enough crowding in the mandibular arch indicating that extractions

are necessary. In these cases, the molar relationship would be Class I.^{4,7,8,9}

The shape and color of the canines are also important factors to look at before deciding upon canine substitution. The canine is a significantly larger tooth than the lateral incisor, and its buccal surface is more convex. Because of this size discrepancy, an anterior tooth size excess in the maxillary arch would be created and anatomical adjustment must be performed to reduce the discrepancy and to establish an anterior occlusion with a normal overbite and overjet relationship.¹⁴

If the patient's lip level when smiling is in a position that allows the gingival margins to be visible, the gingival margin of the canine should be placed 0.5-1.0 mm incisal to the gingival margin of the central incisor. Also, according to Senty, if the patient has a high smile line, a prominent canine root eminence could generate an esthetic concern.^{9,10}

An advantage of closing space by canine substitution is the permanence of the final result, eliminating the need for long-term temporary restorations that are often needed until the patient is old enough for a permanent prosthesis, and avoiding the long-term maintenance required for the prosthesis over the patient's lifetime which can be costly. Multiple clinicians have found that patients who had canine substitution were also healthier periodontally than those who had a prosthesis placed. And some studies have shown that patients who had canine substitution were more satisfied with the appearance of their teeth than those who had a prosthesis placed.

The disadvantages of canine substitution include the need to remove tooth structure on the canine and first premolar, and potential additional expenses if the canines need cosmetic bonding to improve the esthetic result.^{11,15} Robertsson and Mohlin found in their study that patients who had canine substitution were dissatisfied with the lack of color balance of the maxillary canine and the adjacent teeth.¹⁶

This treatment approach includes

orthodontic treatment with fixed appliances for the closing of the spaces and replacing the congenitally missing maxillary lateral incisors by the canines and the canines by the first premolars, respectively. It is a common and popular approach which can lead to very esthetic and satisfying results nowadays with the aid of esthetic and restorative dentistry. The most difficult task in substituting canines for missing lateral incisors is the achievement of an excellent esthetic and functional outcome that resembles an intact natural dentition.

CASE REPORT:

Findings and Diagnosis: The patient presented at the age of 15 years for a consult for orthodontic treatment in anterior teeth. She is disturbed of the unsatisfactory aesthetic situation in the anterior maxillary teeth. The lateral incisors were missing. As a result of the long period of time between the eruption of teeth 13 and 23 and the day of consulting, both teeth were mesially drifted to the physiological place of both lateral incisors. The teeth 13 and 23 erupted mesial to their physiological eruption place and thus took the place of the missing lateral Incisors. Teeth 12 and 22 were missing, which bothered the patient the most.

The profile is harmonic in both the sagittal as well as in the vertical dimension (**FIG 1a, b**). The intra-oral images show the beginning of the treatment, an Angle Class I occlusion of the first molars on both sides (**FIG 2a-d**). In a frontal image, the canines are at the position of the lateral incisors. The gaps for the missing lateral incisors are closed. In the upper arch there are rotations of the premolars both right and left. In the Lower arch crowding exists, about a 7mm.

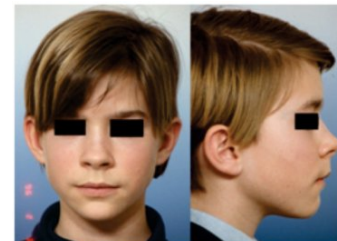

Fig 1a, b: Extra-oral images show a harmonious profile in the vertical, sagittal and transversal.

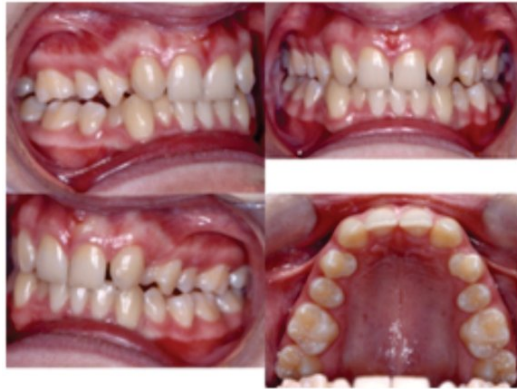

Fig 2a-d: Agenesis of teeth 12 and 22 with significant crowding in the mandibular arch. Gap opening for the missing teeth is hardly possible with simultaneous resolution of crowding in the lower jaw. The almost closed gaps for the lateral incisors orthodontic be closed, so that the teeth 13 and 23 are positioned at the location of the missing teeth. In the lower jaw the teeth 34 and 44 extracted in return.

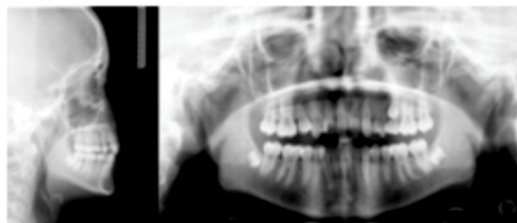


Fig 3,4: All teeth are present, with the exception of 11 and 12.

The periodontal situation was good as clinically seen. The Panoramic X-ray shows the presence of all teeth except for the both lateral incisors. The periodontal situation was radiographically good and the Bone condition shows that there is no Periodontal Disease (**FIG 3**). The cephalogram shows no skeletal Abnormalities. The anterior maxilla is in normal axis, while the anterior mandibular teeth were retroclined (**FIG 4**).

Treatment Planning: To produce a seamless, aesthetically pleasing maxillary arch there are two alternatives:

1. Non-extraction therapy: gap opening for the prosthetic replacement of 12 and 22. The necessary space for harmonious formation in the maxillary dental arch is obtained by conservative-space gaining.
2. Extraction therapy and Orthodontic space

closure: Positioning of the canine teeth in place of the lateral incisors. This approach requires a balancing extraction of two premolars in the mandible. The parents of the patient were alerted of the advantages and disadvantages of both alternatives discussed. They ultimately chose for the extraction therapy in the mandible and close the gap in the upper jaw.

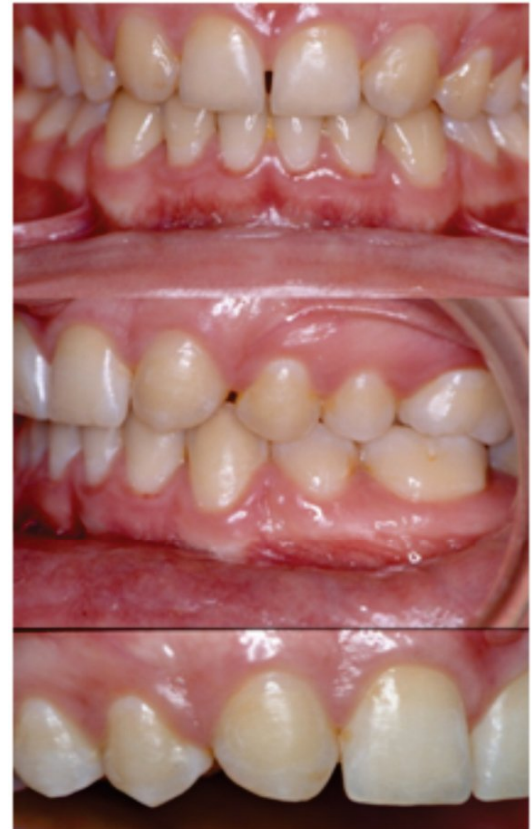

Fig 5a-c: Intraoral photographs in occlusion. There are Class-I occlusion of the 6 with physiological overjet and overbite.

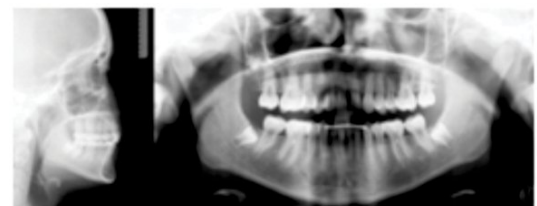


Fig-6,7: Cephalogram after the treatment.

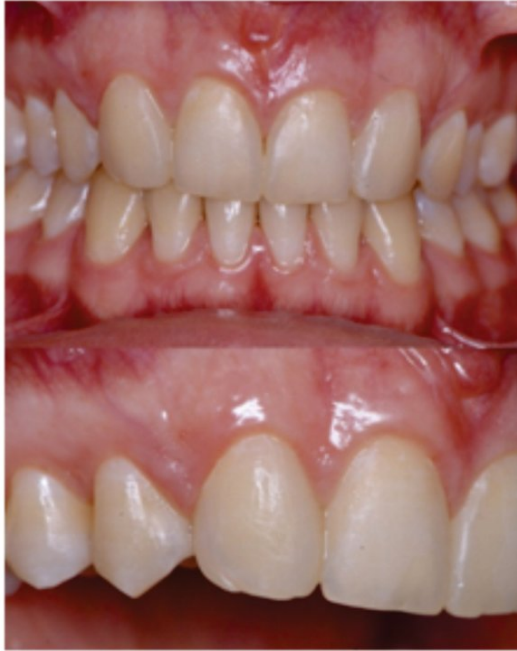

Fig 8a-c: The intra-oral images show the situation after the end of treatment

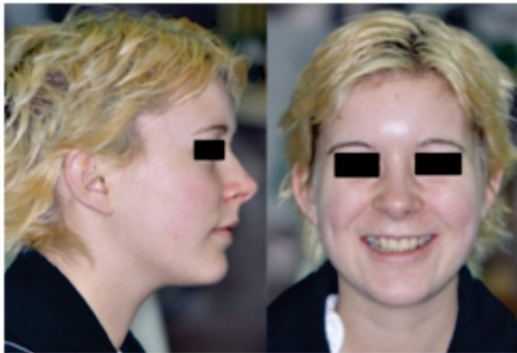

Fig 9a-b: The extraoral images show a beautiful smile with a natural harmonious profile.

Therapeutic approach

In the orthodontic phase, a fixed appliance (0.022 x 0.028 slot brackets) was bonded for the planned tooth movements. In the lower jaw, the teeth 34 and 44 were extracted as a place for obtaining the resolution of crowding. Before the debonding of the MB apparatus an interdisciplinary discussion with the attending colleagues, shape change of the canines was performed to lateral incisors and their characteristics. After twelve months of orthodontic treatment all

objectives were achieved. The arches were formed. The overjet in the sagittal and vertical dimension was in the physiological range (**FIG 5a-c**).

The cephalogram (**FIG-6**) shows the dental changes; due to the slight retrusion of the fronts in both jaws, there was a relatively small, lingual tipping of both fronts. The Panoramic X-ray shows no abnormalities, and no root resorption were recorded (**FIG 7**). To improve the dentofacial aesthetics in the anterior region, the shape of the canines was changed to the lateral incisors with composite (**FIG 8a-c**, **FIG 9a-b**). For retention we bonded a fixed Retainer in the mandibular arch from canine to canine. In addition, retention plates were used in the maxilla and mandible.

DISCUSSION:

A significant number of people in the population are congenitally missing permanent maxillary lateral incisors.¹⁻⁵ The demand for orthodontic treatment by these people is high because of the obvious impact that this condition has on both dental and facial esthetics.⁶ This is a challenging situation that every orthodontist will encounter on a regular basis.

Multiple authors in the literature suggest that the gingival margins of the central incisors should be at the same level as the canines, with those of the lateral incisors positioned more incisal. However, it is important to keep in mind that this is only their expert opinion of what the ideal gingival margin relationship is, not what it naturally is, and that none of these studies directly measured the natural relationship between the gingival margins of the maxillary central and lateral incisors. Many of these authors formed their opinion based on surveys where people ranked photographs of the smile, with only the gingival margin relationship between the maxillary central and lateral incisors being altered.^{2,6,10,11,15}

Charruel et al investigated 103 patients using computer software and digital ph between the maxillary central and lateral

incisors. They found the gingival margin of the maxillary lateral incisor on average to be 0.68 mm incisal to the gingival margin of the maxillary central incisor.¹⁷ This is closer to the finding of the present study (0.39 mm incisal) than what Chu et al found in their study. otographs of plaster casts to obtain measurements of the gingival margin relationship.¹⁸

Charruel et al, also found in their study that about four percent of maxillary lateral incisors had their gingival margin apical to the gingival margin of the maxillary central incisor, 15% were at the same level, 54% were between 0.0 - 1.0 mm incisal, and 27% were greater than 1.0 mm incisal.¹⁷

In a study by An et al, previous orthodontic treatment was one of their exclusion criteria. They examined 120 dental students and found 14.60% of gingival margins of maxillary lateral incisors to be apical to the gingival margins of maxillary central incisors, 25.90% were at the same level, and 59.40% were incisal. The present study had a similar finding, in that it found 59.30% of gingival margins of mesial erupted maxillary canines to be incisal to the gingival margins of maxillary central incisors.¹⁹

Multiple authors in the literature suggest that the gingival margins of the central incisors should be at the same level as the canines, with those of the lateral incisors positioned more incisal. However, it is important to keep in mind that this is only their expert opinion of what the ideal gingival margin relationship is, not what it naturally is, and that none of these studies directly measured the natural relationship between the gingival margins of the maxillary central and lateral incisors. Many of these authors formed their opinion based on surveys where people ranked photographs of the smile, with only the gingival margin relationship between the maxillary central and lateral incisors being altered.^{4,8,9,10,11,15}

Angle Class II malocclusion with maxillary prognathism is considered as an

obvious indication for space closure. In this occlusal pattern, the molar relationship remains Class II and the first premolars are located in the traditional canine position. A Class I malocclusion with sufficiently crowding where mandibular extractions are required is also an indication for space closure.^{10,11,16}

Generally, whenever teeth of the mandibular arch need to be extracted for orthodontic reasons, such as severe crowding or protrusion, space closure is the suitable option. Another indication is a patient with full-lip profile when anterior teeth are severely protruded, or tipped labially or a patient with a balanced profile with normally inclined anterior teeth and minimal or no space available in the maxillary arch. When there is generalized spacing in the arch, closing the spaces is not indicated, but on the contrary, when crowding is present, space closure is the suitable option.²⁰

The congenital absence of lateral incisors in Class III malocclusions is generally considered as a contraindication for orthodontic space closure, especially in patients with retrognathic profile type. These cases usually have an edge to edge or negative overjet which may be worsened if the spaces are closed as the maxillary arch contracts.

In a patient with a high smile line, the demand on esthetic result is enhanced as the gingival levels are more visible.^{21,22} These patients should be treated with orthodontic space closure, as it results in an esthetically more attractive outcome, and should not be treated with space reopening and lateral incisor implant placement, especially young patients. It is inconceivable that such a technique can achieve the long-term occlusal, gingival, and periodontal results in the esthetic zone that are seen with space closure.²² Unilateral absence. These cases seem to be more difficult

To manage than the bilateral absence because it is not easy to achieve a midline symmetry which contributes to better dental harmony. In addition, the contralateral

incisor is often pegged-shaped or diminutive with a thin and short root. The causes size discrepancy between the anterior teeth.²³ In such circumstances, extraction of the contralateral incisor and normal space closure may be a better option as it facilitates the maintenance of mid line and dental symmetry of the maxilla.^{23,24}

Esthetics as well as occlusion must be considered in the final orthodontic positioning of the teeth adjacent to the edentulous space. To satisfy the "golden proportion" principle of esthetics, the space for the maxillary lateral incisor should be approximately two-thirds of the width of the central incisor.^{11,12,13} However, if the patient is missing only one maxillary lateral incisor, the space required to achieve symmetrical esthetics and occlusion is primarily dictated by the width of the contralateral incisor.²⁵

Clinical experience has shown us that a good clinical outcome depends on various factors such as knowledge and professional skills involved in the treatment as well as the combination of orthodontic and esthetic dentistry techniques, the patient's cooperation and age.^{24,25} The orthodontist should move the teeth mesially, characterizing the canine in the lateral incisor, considering torque and extrusion. The occlusion of a patient with lateral incisors agenesis orthodontically treated with posterior Teeth's mesialization is satisfactory from the aesthetic and functional point of view. Long-term studies evaluated the periodontal status and occlusal function from 2 to 25 years post-treatment,^{18,21} concluding that there is no functional overload in the premolar. However, in some patients, due to the discrepancy in teeth's size (Bolton), the case may be ended with a little overjet and overbite. Regarding retention, Hawley is usually utilized for the upper arch and a 3x3 in the lower arch, for continuous use.

CONCLUSIONS:

Orthodontic space closure is a valid treatment option in cases of congenitally missing maxillary lateral incisors and

depends on the evaluation of profile, state of occlusion, and the available space.

Mildly convex profile

Class II malocclusion

A tendency towards maxillary crowding in a patient with a well-balanced profile and normally inclined anterior teeth

Marked maxillary crowding or protrusion

Canines and premolars of similar size

Dentoalveolar protrusion

In conclusion, the timely cooperation of dentists and orthodontists allows the occlusal assessment, as well as the detection of other orthodontic problems, such as the absence of third molars and possibly pre-existing disparities in upper midline. Bearing in mind the final result in regard to the occlusion and profile, the thorough assessment that we have described should point to the most appropriate solution for the individual patient case.

It is important that the orthodontist together with the other specialists frame a treatment objectives which are realistic and meet the needs of the patient. Constant interaction and communication among the team members and the patient at all levels of treatment are the keys to the success of the interdisciplinary treatment.

References:

1. Kennedy DB. Orthodontic management of missing teeth. *J Can Dent Assoc* 1999;65:548-50
2. Armbruster PC, Gardiner DM, Whitley JB Jr, Flerra J. The congenitally missing upper lateral incisor: part 1: esthetic judgment of treatment options. *World J Orthod*. 2005; 6:369-75.
3. Rendon J. Effect of congenitally missing lateral incisors on the eruption and impaction of the maxillary canine: Saint Louis University; 2005.
4. Kokich VO Jr. Congenitally missing teeth: orthodontic management in the adolescent patient. *Am J Orthod Dentofacial Orthop* 2002;121:594-5.
5. Turpin DL. Treatment of missing lateral incisors (Editorial). *Am J Orthod Dentofac Orthop* 2004; 125: 129.
6. Kokich VG, Spear FM. Guidelines of managing the orthodontic-restorative patient. *Semin Orthod* 1997;3:3-20
7. Araújo EA, Oliveira DD, Araújo MT. Diagnostic protocol in cases of congenitally missing maxillary lateral incisors. *World J*

- Orthod 2006;7(4):376-88
8. Zachrisson BU. Improving orthodontic results in cases with maxillary incisors missing. Am J Orthod 1978;73:274-89.
 9. M. Rosa and B. U. Zachrisson, "The space-closure alternative for missing maxillary lateral incisors: an update," Journal of Clinical Orthodontics, vol. 44, no. 9, pp. 540-561, 2010
 10. Zachrisson BU, Rosa M, Toreskog S. Congenitally missing maxillary lateral incisors: canine substitution. Point. Am J Orthod Dentofacial Orthop. 2011;139:434-45.
 11. Kokich VO, Kinzer GA, Janakiesvski J. Congenitally missing lateral incisors: Restorative replacement. Am J Orthod Dentofacial Orthop 2011 April; Vol 139(4):435-445
 12. Lewis BR, Gahan MJ, Hodge TM, Moore D. The orthodontic-restorative interface: 2. Compensating for variations in tooth number and shape. Dent Update 2010 Apr;37(3):138-40
 13. Zachrisson BU. Improving the esthetic outcome of canine substitution for missing maxillary lateral incisors. World J Orthod 2007; 8:72-79.
 14. Czochrowska EM, Skaare AB, Stenvik A, Zachrisson BU. Outcome of orthodontic space closure with one maxillary incisor missing. Am J Orthod Dentofac Orthoped 2003; 123: 597-603.
 15. Kokich VO, Jr., Kiyak HA, Shapiro PA. Comparing the perception of dentists and lay people to altered dental esthetics. J Esthet Dent. 1999;11:311-24.
 16. Robertsson S, Mohlin B. The congenitally missing upper lateral incisor. A retrospective study of orthodontic spaceclosure versus restorative treatment. Eur J Orthod 2000; 22:697-710.
 17. Charruel S, Perez C, Foti B, Camps J, Monnet-Corti V. Gingival contour assessment: clinical parameters useful for esthetic diagnosis and treatment. J Periodontol. 2008;79:795-801.
 18. Chu SJ, Tan JH, Stappert CF, Tarnow DP. Gingival zenith positions and levels of the maxillary anterior dentition. J Esthet Restor Dent. 2009;21:113-20.
 19. An KY, Lee JY, Kim SJ, Choi JI. Perception of maxillary anterior esthetics by dental professionals and laypeople and survey of gingival topography in healthy young subjects. Int J Periodontics Restorative Dent. 2009;29:535-41.
 20. Sabri R. Management of missing maxillary lateral incisors. J Am Dent Assoc. 1999;130:80-4.
 21. Sarver DM, Ackerman MB. Dynamic smile visualization and quantification: Part 2. Smile analysis and treatment strategies. Am J Orthod Dentofacial Orthop. 2003;124:116-27.
 22. L. Savarrio and G. T. McIntyre, "To open or to close space—that is the missing lateral incisor question," Dental Update, vol. 32, no. 1, pp. 16-25, 2005.
 23. G. Richardson and K. A. Russell, "Congenitally missing maxillary lateral incisors and orthodontic treatment considerations for the single-tooth implant," Journal of the Canadian Dental Association, vol. 67, no. 1, pp. 25-28, 2001.
 24. Spear FM, Kokich VG, Matthews DP. Interdisciplinary management of anterior dental esthetics. JADA 2006;137:160-169
 25. Springer NC, Chang C, Fields HW, Beck FM, Firestone AR, Rosenstiel S, Christensen JC. Smile esthetics from the layperson's perspective. Am J Orthod Dentofacial Orthop. 2011;139:e91-e101.

Cite this Article as: Abu-Hussein M, Watted N. Congenitally missing upper laterals. Clinical considerations: Orthodontic space closure. Int Res Pub Med Sci 2015; 1(3):82-89.