ISSN : e- ISSN 2395-3950, p-ISSN 2395-440X

Congenital Giant Lipoma Neck: A Rare Case Report

[1] Kamal N Rattan, [2] SPS Yadav, [3] Priya Malik

[1] Senior Professor, Department Of Pediatric Surgery, PGIMS, Rohtak
[2] Senior Professor, Department Of Otolaryngology, PGIMS, Rohtak
[3] Senior Resident, Department Of Otolaryngology, PGIMS, Rohtak

ABSTRACT:

Lipomas are adipose tumors, which are one of the commonest and most benign of all tumors. The incidence of lipoma is quite common, but mostly they are of small size and remain asymptomatic for years. They may arise in all parts of the body, but their occurrence in the head and neck, however, is relatively rare. Head and neck lipomas in the pediatric population are rarely described in the literature. Surgical excision of lipoma is often used as the definitive treatment modality. We here report a rare case of congenital giant lipoma located in the anterior part of the neck of a 3 year old female child.

Key-words: Lipoma, Mass, Neck.

Corresponding Author: Dr Priya Malik, Senior Resident, Department Of Otolaryngology, PGIMS, Rohtak. Email: drpriyamalik09@gmail.com

INTRODUCTION:

Lipomas are the commonest encountered benign mesenchymal tumors, arising in any location, where fat is normally present, also known as a "universal tumor" or a "ubiquitous tumor," however, they are mostly of small size and remain asymptomatic for years.[1] Cheek is the most favored sites in head and neck region followed by the tongue, floor of the mouth, buccal sulcus, vestibule, lip, palate and gingiva.[2]

CASE REPORT:

Parents of a three year old female child reported to complain of swelling of the anterior neck, which was present since birth. It gradually increased in size over time to the present size. There was no history of associated pain, fever, difficulty in swallowing, difficulty in breathing, restricted neck movement. On clinical examination there was a diffuse swelling of approximate size 8 X 10 cm, in the anterior part of the neck. It was of smooth surface, overlying skin was stretched without signs of inflammation or prominent veins **(Fig.1)**. On palpation it had normal temperature, non-tender, soft in consistency, mobile, with overlying skin free. There was no noticeable lymphadenopathy or other palpable masses, and oropharynx was normal. FNAC was inconclusive. A CT scan of the soft tissue neck was recommended, it revealed a 10 cm X 8 cm mass in transverse and longitudinal dimensions, respectively. The mass was well-circumscribed and located in the anterior neck without evidence of invasion of adjacent structures. The density of the mass on the contrast enhanced computed tomography suggested that the majority of the tumor was composed of fat **(Fig.2&3)**. Other investigations done were Hb-10.1 mg%, urine complete examination normal, T3, T4 and TSH were also normal. Surgery was planned, under general anesthesia; the anterior neck was exposed and accessed via an elliptical incision, meticulous dissection revealed an encapsulated mass, which was yellow in color, well circumscribed, without invasion of surrounding structures **(Fig.4)**. The mass was enucleated followed by excision of the excess skin, the mass measured 10 cm X 8 cm X 6 cm. Primary closures were done in layers and pressure dressing was given to prevent hematoma

formation. The specimen was submitted for histopathological examination and reported it as lipoma **(Fig.5)**. Postoperative recovery was uneventful.

DISCUSSION:

Lipomas are benign mesenchymal tumors histologically similar to mature adipose tissue. There is a hamartomatous proliferation of mature fat cells, however the presence of fibrous capsule helps to differentiate them from simple fat aggregations.[3] Lipomas have been identified in all age groups but usually appear between 40 and 60 years of age. Solitary lipomas are more common in women and multiple tumors (referred to as lipomatosis) are more common in men. Lipomas may be located in all parts of the body and may be classified as superficial or deep based on the site of origin. Lipomas are most commonly located on the back, followed by arm, shoulder, anterior chest wall, breast, thigh, abdominal wall, legs, forehead and face. Most lipomas present as a painless, mobile, palpable masses with a characteristic soft, doughy feel which are often overlooked by patients till they become an appreciable mass without any symptoms and cause few problems other than those of a localized mass and cosmetic concerns.[4] Clinical features vary greatly depending upon the lesion's size, location and rate of growth. Lipomas appear to be associated with trauma, but it has not been determined whether the trauma causes the tumor or if the discovery of the tumor is incidental.[5] Rate of growth, size, location, consistency and attachment to adjacent tissues differentiate benign from malignant masses.

Grossly, lipomas are soft, yellow, smooth, mobile encapsulated and occasionally lobulated subcutaneous masses. Microscopically, lipomas are composed of mature adipocytes arranged in lobules, many of which are surrounded by a fibrous capsule. Four other types of lipomas may be noted on biopsy specimen like angiolipomas, pleomorphic lipomas, spindle cell lipomas and adenolipoma.[6] Sometimes lipomas are associated with syndromes like multiple lipomatosis[7] (lipoma over the extremities and trunk), Gardner's syndrome (intestinal polyposis, cysts, osteomas), Madelung's disease (lipomatosis of the neck, head, shoulders and proximal extremities), Dercum's disease (multiple painful subcutaneous lipomas).[8] CT and MRI helps in locating the extent of lipoma. MR imaging is better than CT scan, having superior soft tissue contrast resolution and clear definition of the location and longitudinal extent of the mass. It is particularly important in the oral facial region where the margins of lipoma are commonly ill defined, because these lesions often are surrounded by normal fat tissue and have a very thin capsule.[9]

Treatment options available for lipomas are non excisional and excisional. Lipomas are mostly excised. Complications from surgical excision include hematoma, ecchymosis, infection, and deformity, damage to adjacent structures, excessive scarring and fat embolus. Recurrence after excision occurs if residual tumor, including the capsule, remains after excision depending upon location and extent of the resection, occurs in less than five percent. Steroid injections are also used, mostly for the treatment of smaller lipomas, but may require several injections and may depigment the overlying skin. Liposuction is other option, preferred due to less scarring.[10] In neck lies major blood vessels and the nerves and aerodigestive tract, therefore the knowledge of anatomy and meticulous surgical technique should be expertise of working surgeon. Due to the large size of the tumor, and nearby major blood vessel and aerodigestive tract, it was very challenging for us to excise tumor as much as possible, taking care of nearby structures. The differential diagnosis of lipoma is epidermal cysts, nodular subcutaneous fat necrosis, subcutaneous tumors, sarcoidosis, nodular fascitis, liposarcomas, erythema nodosum, vasculitic nodules, rheumatic nodules, infections, metastatic disease and

hematomas.

CONCLUSION:

Lipomas are the most commonly encountered benign mesenchymal tumors. Giant lipoma of the anterior neck is extremely rare, especially in pediatric age group, but should be considered among differential diagnosis. Surgical management of this tumor is challenging and should be performed by an experienced surgeon. Even asymptomatic lipomas, this large size should be removed not only for cosmetic purposes but also for future transformation into liposarcoma.

Fig 1. Photograph showing swelling anterior neck

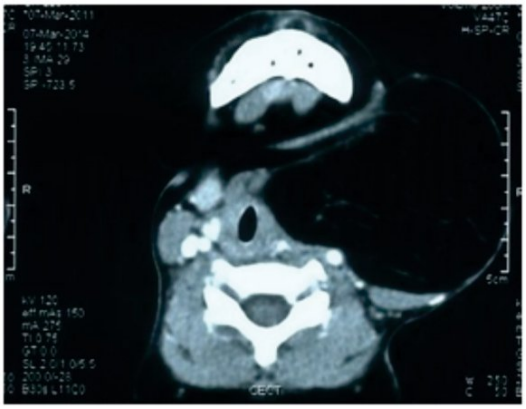

Fig 2. CECT Neck – Axial view showing extent of mass.

Fig 3. CECT Neck-Sagittal view showing extent of mass.

Fig 4. An Intraoperative photograph showing precise enucleation of mass

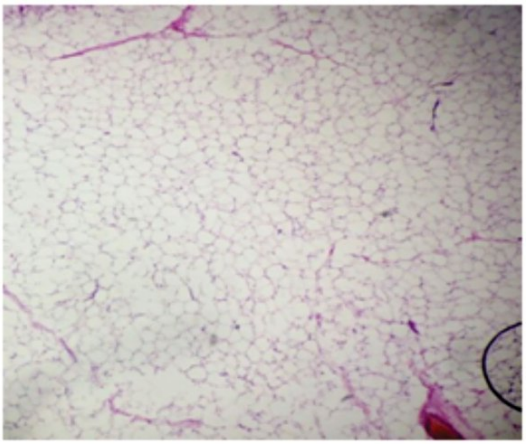

Fig 5. Histopathology of lipoma showing mature adipocytes, enclosed in thin capsule

References:

1. Kransdorf MJ. Benign soft-tissue tumors in a large referral population: distribution of specific diagnosis by age, sex, and location, Am J Roentgenol, 1995;164:395-402.
2. Ayasaka N, Chino T, Anot M. Infiltrating lipoma of the mental region: report of a case, Bri Oral Maxillofac Surg, 1993;31:388-90.
3. Marx R, Stern D. Oral and maxillofacial pathology: A rationale for diagnosis and treatment, Quint essence Publishing Co, Inc, 2003;404-05.
4. Del AC, Felipo F. Adenolipoma of the skin. Dermatol Online J, 2004;10:09-15.
5. Ashley DJB. Evans' Histological Appearances of Tumors. 3rd Ed. Edinburgh: Churchill & Livingston;1978:54.
6. Piatteli A, Fioroni M, Rubini C. Intramuscular lipoma of the cheek: a case report, J Oral Maxillofac Surg, 2000;58:817-19.
7. Kenawi MM.Squeeze delivery' excision of subcutaneous lipoma related to anatomic site, Br J Surg, 1995;82:1649-50.
8. Austin R, Mack G. Infiltrating (intramuscular) lipoma and angiolipoma -A clinicopathologic study of six cases, Arch Surg, 1980;115:281-84.
9. Field LM. Lipo-suction surgery: A review, J Dermatol Surg Oncol, 1984;10:530–38.
10. Weiss SW. Lipomatoustumors, Monogr Pathol, 1996;38:207–39.

Cite this Article as: Rattan KN, Yadav SPS, Malik P. Coengenital giant lipoma neck: A rare case report. Int Res Pub Med Sci 2015; 1(3):99-102.