

Various Venacaval Anomalies: Case Series Review Of Literature.

¹Sagar NS, ²KB Gehlot, ³D Sunil Kumar, ⁴NK Kardam, ⁵Shilpi Mittal

^{1,3,5}Resident Doctor, ²Assistant professor, ⁴Professor and HOD, Department of Radio-diagnosis, RNT Medical College and MB Hospital, Udaipur, Rajasthan.

ABSTRACT

Most malformations of venacavae are accidental findings in routine thoracic & abdomen imaging. Here we report a series of 5 cases diagnosed during routine computed tomography in the patients referred to our department for various ailments. We found 1) left persistent inferior venacava with hemiazygous continuation draining into the coronary sinus via left persistent SVC; 2) Absent infrahepatic IVC with left sided IVC and situs ambiguous; 3) left persistent SVC; 4) Absent infra renal IVC with lower extremity drainage and 5) Left persistent SVC with anomalous pulmonary vein. Consideration of these anatomical variations is important during surgical and interventional procedures, like renal transplant, central venous catheterization cardiac pacemaker implantation. In all our cases vena caval anomalies were incidental finding and the 3D reconstruction is very useful for better delineation of vascular course, which will help in interventional procedures.

Key-words:-Venacaval variations, Double Inferior venacava, persistent left SVC, azygous and hemiazygous continuation.

Corresponding author Dr N.S. Sagar Room no 14, PG boys hostel, RNT medical college and MB hospital campus, Udaipur 313001 Email- sagarnsatpute@gmail.com

INTRODUCTION

Most malformations of vena cavae are incidental findings in routine thoracic & abdomen imaging. Radiologists often encounter these anomalies unexpectedly. Anomalies of the IVC occur in less than 1% of patients and can be readily recognized on multidetector row CT and MR angiography.¹ Among these, left IVC prevalence is 0.2%–0.5%,² double IVC 0.2%–3%,² and prevalence of azygos continuation of IVC is 0.6%.³ A persistent left SVC is an incidental finding in less than 0.5% of the general population, but occurs in approximately 4% of patients with congenital heart disease.

With advances in non-invasive vascular imaging, anatomical variants and anomalies of the IVC have become more commonly recognized in routine practice. An accurate diagnosis of such a congenital variant, as well as other anatomical variations of the SVC & IVC, may have increased importance in the planning of thoracic & abdominal surgery, liver or kidney transplantation as well as interventional or diagnostic procedures such as filter placement, varicocele sclerotherapy and renal venous sampling.

Case-History:

Case-1: A 52 yr old female patient came to outpatient department with fever and abdominal pain over the epigastric region. The physical examination and laboratory tests provided no significant findings. We proceeded with CT imaging of the abdomen, which revealed liver abscess in left lobe of liver. Incidentally, in addition to the usual right-sided IVC, we found another tubular channel having an enhancement similar to IVC, originating from the left common iliac vein into which left renal vein was draining and it continued into the thorax as hemiazygos continuation. **(Fig-1)** The hemiazygos drained into the coronary sinus via left persistent superior venacava. So, on CT imaging a left inferior venacava with hemiazygos continuation into coronary sinus was diagnosed. There was no anastomosis between the two venacavae.

Case-2: A 40 year old male presented to our department with complaints of dyspnea with no other significant finding in the chest, but incidentally on extended abdominal scan we found, situs ambiguous (heart and liver on the left, spleen bifurcated and on the right side), absent infra hepatic IVC, persistent left IVC and left SVC. Lower limb and both kidneys were drained by left persistent IVC, which finally drained into the coronary sinus via hemiazygos continuation **(Fig-2)**. This moiety also received blood from head and neck via the persistent left SVC. The patient was having the history of a prior valvular disease of the heart.

Case-3: A 8 year old female child presented to our department with acute dyspnea and suspected foreign body inhalation. On CT chest there was a foreign body in left principle bronchus causing near complete collapse of the left lung. Incidentally, we found left persistent SVC draining into the coronary sinus without any communication with right SVC **(Fig-3)**.

Case-4: A 60 yr old female patient came to outpatient department with abdominal swelling for which she was referred to our department; ultrasonography was done where she found to have adnexal masses and pelvic ascites. To see the extension we proceeded with CT imaging of the abdomen and found an adnexal solid cystic mass and pelvic ascites. Incidentally, we found infra renal IVC and bilateral common iliac veins were absent. Bilateral external and internal iliac veins were drained via the vertebral plexus as a hemiazygos continuation to coronary sinus **(Fig-4)**.

Case-5: A 47 yr old female came to us for CT pulmonary angiography with complaints of dyspnoea. Angiography was normal, however incidentally we found left persistent SVC; without any communication with right SVC and right superior pulmonary vein draining into the right SVC. The patient was having the history of a congenital heart disease (Atrial septal defect) **(Fig-5,6)**.

DISCUSSION**Variations in development of IVC:****Left IVC**

A left IVC results from regression of the right

supra-cardinal vein with persistence of the left supra-cardinal vein. Typically, the left IVC joins the left renal vein, which crosses anterior to the aorta in the normal fashion, uniting with the right renal vein to form a normal right-sided prerenal IVC.

Double IVC

Duplication of the IVC results from persistence of both supracardinal veins. The left IVC typically ends at the left renal vein, which crosses anterior to the aorta in the normal fashion to join the right IVC.

Azygos continuation of the IVC

Azygos continuation of the IVC has also been termed absence of the hepatic segment of the IVC with azygos continuation.³ The embryonic event is theorized to be failure to form the right sub-cardinal–hepatic anastomosis, with resulting atrophy of the right sub-cardinal vein. Consequently, blood is shunted from the supra-sub-cardinal anastomosis through the retro-crural azygos vein, which is partially derived from the thoracic segment of the right supra-cardinal vein.

Absent Infra-renal IVC with preservation of the supra-renal segment

Several reports have described absence of the entire IVC⁴ or absence of the infra-renal IVC with preservation of the supra-renal segment.⁵ Absence of the entire posthepatic IVC suggests that all three paired venous systems failed to develop properly. Absence of the infrarenal IVC implies failure of development of the posterior cardinal and

supracardinal veins.

Azygos and hemiazygos continuation of the IVC

These anomalies may be isolated or associated with other anomalies. Azygos continuation is common in patients with polysplenia (left isomerism) but rare in patients with asplenia (right isomerism).^{6,7} Other associated anomalies have included abnormal abdominal situs and a left or duplicated IVC. The hepatic segment of the IVC is absent or hypoplastic, and this condition must be documented to exclude other causes of an enlarged azygos vein. Azygos continuation has also been reported in association with a azygos lobe. Hemiazygos continuation of a left-sided IVC has several variations including three possible routes for blood in the hemiazygos vein to reach the right atrium. In the first route, the hemiazygos vein drains into the azygos vein at T8–T9. In this case, the findings on more cephalad levels are similar to azygos continuation with enlargement of the distal azygos vein. The hemiazygos vein is also enlarged. The second route involves a persistent left SVC, and blood flows from the hemiazygos vein into the accessory hemiazygos vein and left SVC and then into the coronary sinus, all of which are dilated. In the third route, the hemiazygos vein drains to the accessory hemiazygos vein, left superior intercostal vein, and left brachiocephalic vein into a normal right SVC.

Double SVC and Persistent left SVC

A double SVC is the result of persistence of the left anterior cardinal vein. If, in

addition, the normally persistent right cardinal vein regresses, then there is only a left SVC.^{8,9} In most cases, the left SVC is a component of a duplicated SVC. The left brachiocephalic vein is absent, and the right SVC is smaller than the left in 65% of SVC duplications.^{8,9,10}

Clinical Implications: Although anomalous development of varicose veins are not common, they have clinically important consequences in certain settings. The dilated azygos/hemiazygos system shown by chest or abdominal X-ray films can be misinterpreted as a mediastinal or retroperitoneal neoplasm, lymphadenopathy or aortic dissection.¹¹ Anomalies of the IVC were recognized as a possible risk factor for lower limb thrombosis,^{12,13} particularly in young adults. Venostasis due to pathological conditions such as acquired obstruction of the IVC or SVC, the right heart failure, portal hypertension or due to pregnancy can have the same clinical presentation as an azygos/hemiazygos continuation of the IVC.¹⁴ In the case of an azygos/hemiazygos continuation of the IVC, the hepatic veins can drain directly into the right atrium. Radiologically presence of the thrombosed double IVC can be mistaken as a pathological lesion such as paraaortic lymphadenopathy^{15,16} or left pyelo-ureteric dilatation. Not only radiologist but also surgeons dealing with these regions must also be familiar about these anomalies. A high index of suspicion on the part of the surgeon is required to prevent inadvertent injury to these

anomalous veins and to avoid significant hemorrhage during retroperitoneal surgery. Clinically, the significance is in patients with deep vein thrombosis who continue to have recurrent pulmonary embolism despite placement of an IVC filter.¹⁷ In Urology, during donor nephrectomy, usually the left-sided kidney is preferred due to the longer length of the renal vein, but the presence of double IVC or left-sided IVC may shorten the length of the renal vein in the graft that may require an IVC cuff.¹⁸

The presence of these vena caval variations affects decisions concerning shunt placement for portal hypertension and ligation or clipping of the IVC for thromboembolism.¹⁷ A fatal outcome after ligation of the azygos vein in a patient with an azygos continuation of the IVC has been reported.¹⁸ Angiography and cardiac catheterisation can be difficult when this variation is present.¹⁷ A left SVC is most often an incidental finding that is not clinically significant, but patients with a left SVC draining into a coronary sinus that has a narrowed ostium have presented difficulties in introducing IV lines and pacemaker or defibrillator leads.¹⁰ The coronary venous drainage to the heart, however, is then retrograde through the left SVC to the left brachiocephalic vein. When this circumstance is unrecognized, ligation of the left SVC as part of a cardiac surgical procedure has led to acute coronary venous hypertension and myocardial ischemia.^{19,20}

CONCLUSION

The complexity of the venacaval development, with numerous anastomoses formed between the three primitive paired veins, can lead to a wide array of variations in the basic plan of venous return from the thorax, abdomen and lower extremity. Some of these anomalies have significant clinical implications. A working knowledge of vena caval anomalies is essential to avoid diagnostic pitfalls. Scrutiny of these variations should be included in routine scans. An accurate diagnosis of such a congenital variant, may have increased importance in planning abdominal surgery, liver or kidney transplantation as well as interventional or diagnostic procedures such as IVC filter placement, varicocoele sclerotherapy and renal venous sampling.

Conflict of Interest: None.

Funding: Nil.

References

- 1) Chuang VP, Mena CE, Hoskins PA. Congenital anomalies of the inferior vena cava. Review of embryogenesis and presentation of a simplified classification. *Br J Radiol* 1974;47:206–13.
- 2) Phillips E. Embryology, normal anatomy, and anomalies. In: Ferris EJ, Hipona FA, Kahn PC, Phillips E, Shapiro JH, eds. *Venography of the inferior vena cava and its branches*. Baltimore, Md: Williams & Wilkins, 1969; 1-32.
- 3) Ginaldi S, Chuang VP, Wallace S. Absence of hepatic segment of the inferior vena cava with azygous continuation. *J Comput Assist Tomogr* 1980;4:112-114.
- 4) Geley TE, Unsinn KM, Auckenthaller TM, Fink CJ, Gassner I. Azygos continuation of the inferior vena cava in pediatric patients: sonographic demonstration of the renal artery ventral to the azygos vein as a clue to diagnosis. *Am J Roentgenol* 1999; 172:1659-1662.
- 5) D'Archambeau O, Verguts L, Myle J. Congenital absence of the inferior vena cava. *J Belge Radiol* 1990;73:516-517.
- 6) Applegate KE, Goske MJ, Pierce G, Murphy D. Situs revisited: imaging of the heterotaxy syndrome. *RadioGraphics* 1999;19:837–852.
- 7) Ruscazio M, Van Praagh S, Marrass AR, et al. Interrupted inferior vena cava in asplenia syndrome and a review of the hereditary patterns of visceral situs abnormalities. *Am J Cardiol* 1998; 81:111–116.
- 8) Cormier MG, Yedlicka JW, Gray RJ, Moncada R. Congenital anomalies of the superior vena cava: a CT study. *Semin Roentgenol* 1989;24:77–83.
- 9) Cha EM, Khoury GH. Persistent left superior vena cava. *Radiology* 1972;103:375–381.
- 10) Sarodia BD, Stoller JK. Persistent left superior vena cava: case report and literature review. *Respir Care* 2000;45:411–416.
- 11) Meyer DR, Hüppe T, Anderesen R, Friedrich M. Intra- and Infrahepatic Agenesis of the Inferior Vena Cava with Azygos Continuation Accompanied by

- Duplication of the Postrenal Segment. Invest Radiol 1998; 33: 113–16.
- 12) Reinus WR, Gutierrez FR. Duplication of the inferior vena cava in thromboembolic disease. Chest. 1986; 90: 916–918.
 - 13) Kondo Y, Koizumi J, Nishibe M, Muto A, Dardik A, Nishibe T. Deep venous thrombosis caused by congenital absence of the inferior vena cava: report of a case. Surg Today. 2009; 39: 231–234.
 - 14) Martinez Garcia MA, Pastor A, Ferrando D, Nieto ML. Casual Recognition of an Azygous Continuation of the Inferior Vena cava in a Patient with Lung Cancer. Respiration 1999; 66: 66–8.
 - 15) Siegfried, MS, Rochester D, Bernstein JR, Milner JW. Diagnosis of inferior vena cava anomalies by computerized tomography. Comput. Radiol. 1983; 7: 119–123.
 - 16) Royal SA, Callen PW. CT evaluation of IVC and renal vein. Am J Roentgenol 1979; 134: 759–763.
 - 17) Fernandes R, Israel RH. Isolated Azygos Continuation of the Inferior Vena cava in the Elderly. Respiration 2000; 67: 229–33.
 - 18) Effeler DB, Greer AE, Sitters EC. Anomaly of the Vena Cava Inferior. Report of Fatality after Ligation. J Am Med Assoc 1951; 146: 1321–2.
 - 19) Muster AJ, Naheed ZJ, Backer CL, Mavroudis C. Is surgical ligation of an accessory left superior vena cava always safe? Pediatr Cardiol 1998; 19: 352–354.
 - 20) Santoscoy RS, Walters HL III, Ross RD,

Lyons JM, Hakimi M. Coronary sinus ostial atresia with persistent left superior vena cava. Ann Thorac Surg 1996; 61: 879–882

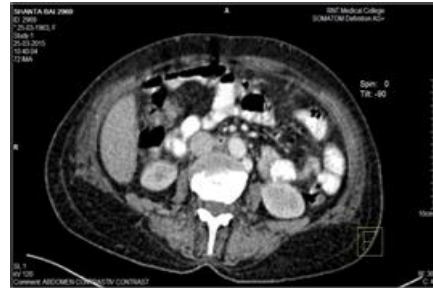

Figure 1. Axial CECT abdomen image shows left persistent IVC posterior-lateral to Aorta.

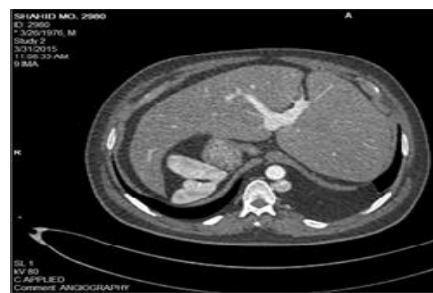

Figure 2. Axial CECT abdomen image shows IVC left lateral to aorta, liver on left side and two spleens on right side. Infra hepatic IVC was absent in this case.

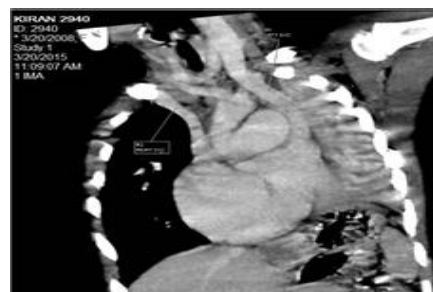

Figure 3. Coronal reformed CECT thorax image shows left persistent SVC draining into Coronary sinus without any communication with the right SVC.

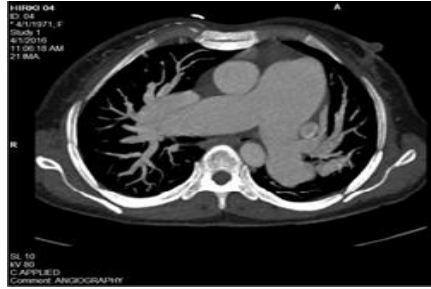


Figure 5. Axial CECT thorax image shows anomalous right superior pulmonary vein draining into right SVC; persistent left SVC left lateral to bifurcation of pulmonary trunk.

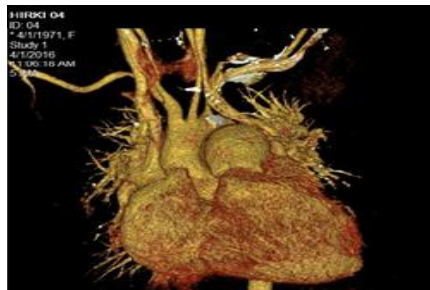

Figure 6. Coronal 3D reformatted image shows persistent left SVC, without any communication with right SVC and anomalous right superior pulmonary vein draining into right SVC.